Abdominal Cavity

- Projects from Sup. Pelvic Apperature to Thoracic diaphragm

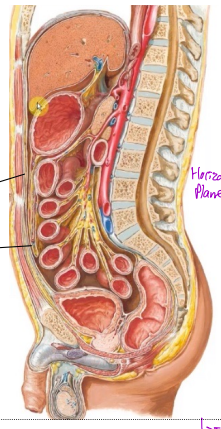

Parietal Peritoneum
↳ lines the Abdominal Cavity

Peritoneum Cavity
↳ No Organs in here
↳ Between Parietal & Visceral Peritoneum

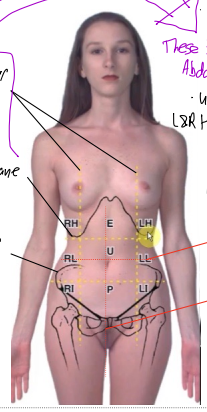

Mid Clavicular Plane
↳ Vertical Plane

Horizontal Plane
- Subcostal Plane
- Transtubercular Plane

These 3 Planes divide Abdomen into 9 Regions
- Umbilical, Epigastric, L&R Hypochondriac, Pubic, L & R Inguinal, L & R Lumbar Regions

Transumbilical Region

Median Plane
↳ Creates 4 Regions

Anterolateral Abdomen

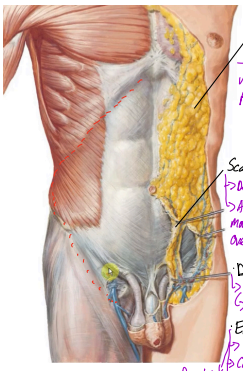

Camper's Fascia
→ Thickness is highly variable in skinny-obese people

Scarpa's Fascia
↳ Dense tissue
↳ Allows for adequate movement of fascia/skin overlay of muscles

Deep Fascia
↳ "Investing Fascia"
↳ Covers muscles

Endoabdominal Fascia
↳ "Transversalis Fascia"
↳ Covers Abdom Cavity, is a thin serous layer
↳ Superficial to the Parietal Peritoneum.

Parietal Peritoneum

Muscles of Abdomen

Abdom muscles

Compression of Abdom viscera does:
- Elevation of diaphragm
- Assist in Defecation, Micturition (urinate), Parturition (child birth).

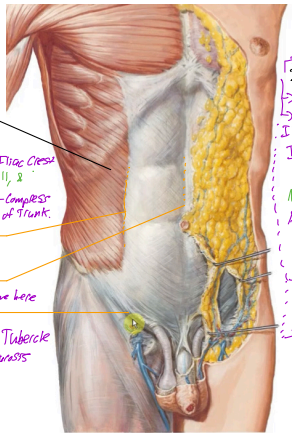

External Oblique m.
↳ Oriented inferio anterior
↳ O - 5-12th rib
I - Linea Alba & Pubic Tubercle & Iliac Crest
→ N - Thoracoabdominal n.'s from T6-T11, & Subcostal n.
→ A - Compress Abdom viscera, Bilateral - Compress abdom wall, Unilateral - Flexion & Rot of Trunk.
↳ Linea Semilunaris
↳ Transition from muscle fibre to Aponeurosis
↳ Linea Alba
↳ Fibres decussate & intermeave here
Inguinal Ligament
↳ Spans from ASIS to Pubic Tubercle
↳ Fold of External Oblique Aponeurosis

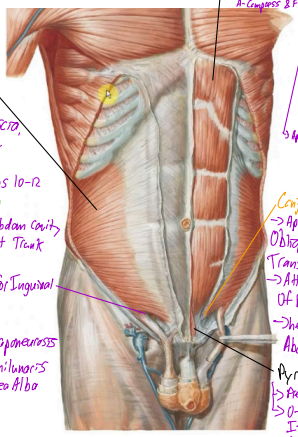

→ In-Sero-posterior
Internal Oblique
↳ Fibres are Transverse
↳ O - Thoracolumbar Fascia, Iliac Crest & Inguinal l.
I - Linea Alba, Pubis, Costal Margins of Ribs 10-12
N - Ventral Rami T5-L1
A - Bilateral - Compress Abdom Cavity, Unilateral - Flex/Rot Trunk
↳ Forms part of roof for Inguinal Canal
→ Like Ex Oblique, aponeurosis begins at Linea Semilunaris & decussates at Linea Alba

Rectus Abdominus
→ Thickness Superior, muscle belies separated by tendinous intersections (of aponeurosis)
→ In between Linea Semilunaris & Linea Alba
↳ O - Pubic Symphysis & Crest
I - Costal Cartilage of 5-8 ribs
N - T6-T12
A - Compress & Flex

Transversus Abdominus
↳ Fibres run Transversely
↳ O - Ribs 7-11, Iliac Crest & Inguinal l.
I - Linea Alba, & fibres w/ Conjoint Tendon
N - Ventral Rami T6-L1
A - Compress Abdom Cavity
↳ Aponeurosis begins at Linea Semilunaris

Conjoint Tendon
→ Aponeurosis of Int. Oblique fuses w/ Transversus Abdom.
→ Attaches to Pectinate of Pubis
→ helps reinforce Abdominal Wall

Pyramidalis m.
↳ Present in 60% of people
↳ O - Pubic Crest
I - Linea Alba
A - Meh

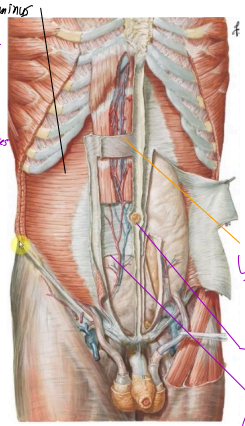

Lipo
Rectus Sheath

Rectus Sheath
↳ Formed by aponeurosis of Oblique & Transversus Abdom m.'s that wraps over Rectus Abdom
→ Umbilical ring; defect in Linea Alba
→ Linea Semilunaris
→ Arcuate line - where fibres of Posterior sheat start to disappear
↳ Anterior Rectus sheath SUP. to Arcuate line is aponeurosis of Ext Oblique, & Ant. ½ aponeurosis of Int. Oblique
↳ Post. Rectus Sheath SUP. to Arcuate line is aponeurosis of Transversus Abdominus & Posterior ½ of Int. Oblique
↳ Ant. Rectus sheat INF to Arcuate line is aponeurosis of ALL Transversus Abdom, Int & Ext oblique
↳ Post. Rectus Sheath INF to Arcuate line is NO aponeurosis, but Peritoal Peritoneum & transverse fascia; MOST WEAK; Beer Belly, due to less support.

Liposuction

- Superficial Fascia adipose removed.
- Closing surgical incisions requires the closing of each fascial layer 1 by 1
↳ Membranous layer of Superficial Fascia will be sutured closed too
↳ Scarpa's Fascia does not fuse to deep fascia, but does fuse to fascia lata
↳ Disallows spread of fluids (blood) from leaking into lower extrem from abdom

Ext Obl → Int Obl → Transvers Abdom → Endoabdom fascia → Parietal Peritoneum
Visceral

Nerves of Anterolateral Wall

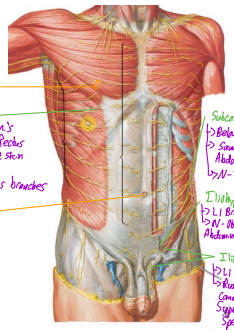

Nipple in T10 dermatome

Thoracoabdominal n. (T6-T11)
↳ Continuation of Intercostal n.'s
↳ N - respective segments for Rectus Abdom & Oblique muscles, & skin sensory
↳ Lateral & Anterior Cutaneous branches (dermatome's)

Umbilicus is in T10 dermatome

Subcostal n.
↳ Below Rib 12
↳ Same as Thoraco-Abdominal n.
↳ N - T12 dermatome

Iliohypogastric n.
↳ L1 Branch
↳ N - Oblique & Transversus Abdominus, & L1 Dermatome

Ilioinguinal n.
↳ L1 Branch
↳ Runs through Inguinal Canal & goes thru Superficial ring, & the Spermatic cord.
→ N - Transverse Abdom & Int. Oblique, & sensory of Skin over Scrotum & medial thigh

Arteries of Anterolateral Wall

Anterolateral wall

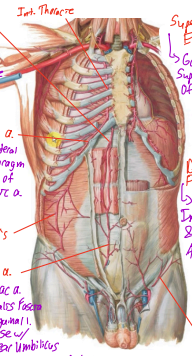

Sup. Epigastric a.
↳ Deep branch of Int. Thoracic a.
↳ S - Muscle & Tissue Superior to Umbilicus

Int. Thoracic

Musculophrenic a.
↳ Supplies Superolateral thorax & diaphragm
↳ Distal branch of Internal Thoracic a.

Lumbar a's

Inf. Epigastric a.
↳ Branch of Ex. Iliac a.
↳ Within Transversalis fascia
↳ Runs up under Inguinal l. & goes to Anastomose w/ Sup. Epigastric near Umbilicus
↳ S - Rectus Abdom & sheath inf. to Umbilicus

Superficial Epigastric
↳ Goes into Superficial Fascia of Abdomen

Deep Circum-Flex Iliac a.
↳ Runs along Inguinal l. & S-lower Abdom Wall

Superficial Circumflex Iliac a.
↳ Branch of Femoral a.

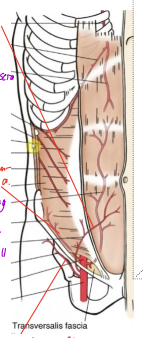

Transversalis fascia

Abdominal Protuberance

- 6 F's:
- Fluid, Food, Feces, Flatulence, Fat, Fetus
- Everted Umbilicus
↳ 'Outy' belly button may be due to chronic pressure
- Striae Gravidarum
↳ Stretch marks

Hernia

- Umbilical Hernia
↳ Congenital → fetal parts
↳ Aquired → obesity, trauma, aging, etc
- Epigastric

Veins of Anterolateral Wall

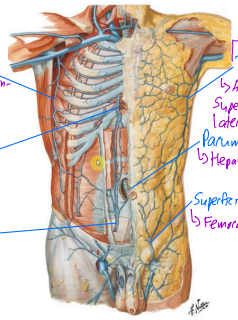

Lateral Thoracic v.
↳ Drainage: Axillar, → Subclavian → Brachiocephalic → etc

Internal Thoracic v.
↳ Drains to Subclavian

Inf. Epigastric
↳ Ex Iliac

→ When enlarged, diagnosis there is a block in venous return
Thoracoepigastric v.
↳ Aponeurosis btwn Superficial Epigastric & Lateral Thoracic v.
Paraumbilical v.
↳ Hepatic Portal v.

Superficial Epigastric
↳ Femoral v.

Lymphatics of Anterolateral Wall

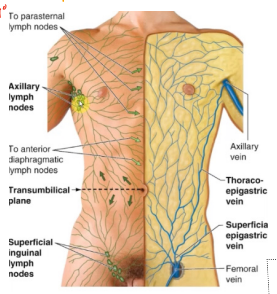

Abdominal Palpation

- Guarding - Patients tendency to tense up
- Inflammation / Visceral Problems can also cause guarding

Incisions

↳ Langer's Lines; incisions parallel to these lines (less scarring) - along the grain
- Laparoscopy - small openings for surgery, motion
- Linea Alba incisions are good for big open cuts, but it is poorly vascularized
- Paramedian Incision - Can work around Rectus Abdominus.
- Grid Iron Incision - Cross
- Subcostal Incision - Good for Stomach, Liver, or Gallbladder

Inguinal

Borders of Inguinal Canal
- Roof - Transversus Abdom & Int. Oblique
- Floor - Aponeurosis of Ext. Oblique
- Post - Conjoint Tendon

Palpation of Superficial Inguinal Ring

- For hernia checking, patient will cough as clinician palpates
↳ If no herniation, No change will be felt.

Inguinal Region

Inguinal Canal
Males
↳ Pathway for Vas Deferens, as well as nerves & blood vessels
Females
↳ Round ligament of uterus

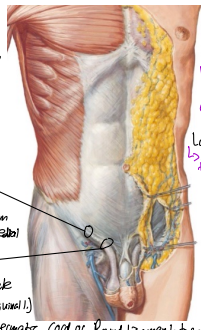

Medial Crus
↳ Attaches the aponeurosis to Pubic Crest

Lateral Crus
↳ Anchores aponeurosis to Pubic Tubercle

Deep Inguinal Ring
↳ Midway down Inguinal l.
↳ Runs just inf to Transversus Abdom
↳ Inf Epigastric a. runs just Medial

Superficial Inguinal Ring
↳ Just Superolateral to Pubic Tubercle
↳ External Oblique aponeurosis (Inguinal l.) will split to form this, allowing for Spermatic Cord or Round ligament to go

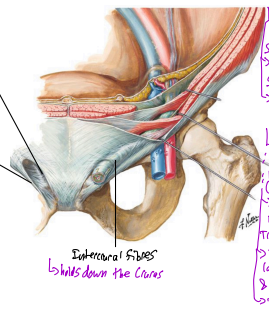

Intercrural fibres
↳ holds down the Crura

- Testes are NOT 'pulled' down, but, without growth around testes so they, eventually, are out of body.

Male Inguinal Canal Dev

Testes will originally form in Endoabdom fascia in post. Abdom wall

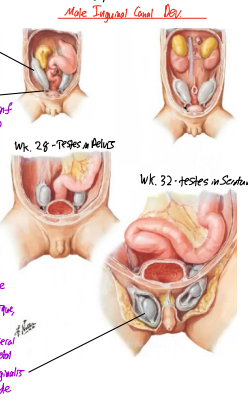

Wk. 28 - Testes in Pelvis

Wk. 32 - Testes in Scrotum

Gubernaculum
↳ Fibre that anchors inf pole of each gonad to Scrotal tissue
↳ Becomes the Scrotal l.
↳ Also forms ovary in females

Processus Vaginalis
↳ Pouch where the parietal peritoneum pushes through (in male dev)
↳ Also pushes some Muscular layers (Oblique, Transversus Abdom)
↳ In Adult, forms visceral layer over testes (Parietal) & Visceral Tunica Vaginalis
↳ Testes pass along side

Female Inguinal Canal Dev

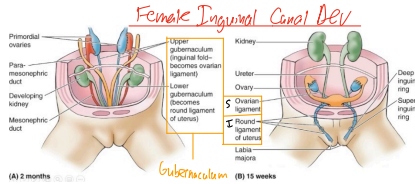

Gubernaculum

- Similar to males, but Processus Vaginalis protrudes to Labia Majora
- Gubernaculum (Sup) fuses to developing uterus, which spans from ovary to uterus (Ovarian ligament), allows for ovaries to NOT pass thru Inguinal Canal
↳ Inf part becomes the Round Ligament of Uterus

Spermatic Cord

Consists of Fascia, muscle, neurovasc that passes thru Superficial Inguinal Ring

- External Spermatic Fascia is part of External Oblique Fascia that was pushed through

Cremaster Muscle
- Direct extension of Int Oblique
- Contraction pulls testes up & relaxation drops testes down to regulate heat. (to help with Spermatogenesis)
- N - Genital Femoral n.
- Cremaster Reflex happens when the Superomedial thigh is touched, causing Ilioinguinal n. to reflex to L1 & Contract the Cremaster Muscle to pull balls up

Testicular a.
- Branch of Abdom Aorta
- Passes thru Inguinal Canal
- S - Testes & Epididymus

Internal Spermatic Fascia
- Transversalis Fascia

Ductus Deferens
- Rigid & Palpable
- Extends from Inf margin of Epididymis to Ejaculatory duct near the Urinary bladder
- Moves Sperm to this duct

Cremasteric Fascia

Pampiniform Plexus
- Heat exchange for Supporting Spermatogenesis
- Plexus converges to form a single Testicular vein in the Abdominal Cavity
- R. Testicular v. drains directly to IVC
- L. drains to L. Renal v.

Mesorchium
- Mesentery of Testes
- Can Twist, which may obstruct BF

Testicular Autonomic Plexus

Sympathetics from T10-11
- Vasomotor to Testicular a.
- Visceral afferents Carry deferred pain
- Stimulates Ductus Deferens for Emission (Process of moving Sperm to ejaculatory duct) & IVC Peristalsis
- Vasomotors, imp q

Parasympathetics
- Derived via Vagus n.
- Allows for relaxation of Ductus Deferens post-emission
- Dec Vasomotor Para

Scrotum

Scrotal Septum

Scrotal Raphe

Dartos Fascia
- Same as Scarpas Fascia (membranous layer of deep aspect of Superficial Fascia of body wall).
- Extends to Perineum & will be called Colles Fascia
- Some smooth muscle to wrinkle skin, which dec ST to reduce heat loss

Parietal Tunica Vaginalis
- Simple Squa Epi that produces Serous Serous fluid to help w/ ST

Visceral Tunica Vaginalis

Genitofemoral n.
- Ant lat. Scrotal Skin
- N - Cremaster Muscle

Ant. Scrotal n
- N - Ant Scrotal Skin

Ant. Scrotal v.
- Ant. Scrotal a's
- S - Ant. Skin
- From Deep Ext Pudendal

Post. Scrotal a's
- Branch from Perineal a. of Int. Pudendal a.
- Post. Scrotal v.'s

Pudendal -> Perineal -> Post. Scrotal n.

Post. Scrotal n.
- Post Scrotal Skin

Post. Femoral Cutaneous n.
- Post. Scrotal Skin

Allows for maturing of Sperm

Epididymus & Testes
- Covered by Visceral Tunica Vaginalis

Head

Tunica Albuginea
- Covered by Tunica Vaginalis

Ductus Deferens

Efferent Ducts

Tail

Testes

Peritoneum

Peritoneum
- Serosa

Parietal Peritoneum
- N - Dermatomal nerves (Ventral Rami Cutaneous Branches) for pain & Somatosensory

Visceral Peritoneum
- NO Somatosensory, N
- N - Afferent Autonomics
- Serosa

Peritoneal Cavity
- No Organs
- Some WBC's & Peritoneal Fluid to help ST
- In Females, the Peritoneal Cavity is open to the Outside world due to the oviducts
- Thus Females more Susceptible to Peritoneal Infection
- Peritoneal Cavity is located in Abdominal Cavity

Intraperitoneal Organs
- Organs are NOT in Peritoneal Cavity, just nearby
- Organs are attached to body wall by an extension of the Peritoneum (allowing vasculature to reach organs)
- 1° Liver, Spleen, Jejunum

Extraperitoneal Organs
- Organs outside of behind the Parietal Peritoneum (Organs Covered by Parietal Peritoneum)
- 1° Bladder & Anus; have layer of Serosa

1° Retroperitoneal Organs
- 1° Kidney, ureter, Renal, Aorta, Vena Cava

2° Retroperitoneal Organs
- Organ initially starts as an Intraperitoneal organ, then post development becomes Retroperitoneal
- 1° Intestines; Duodenum

Peritonitis

Infection

Overproduction of Fluid (ascites)
- Thus fluid is resorbed over time
- Pts should lie down supine, so the fluid doesn't sit in lower abdom areas
- Persistent Adhesions, not Problematic

Cryptochidism Cele

- Cryptorchidism
  - Undescended testes
  - More so in Premature births, meaning the testes are more likely in Abdom Cavity.
- Hydrocele
  - Excess fluid in Testes or along Spermatic Cord
  - Persistent Processus Vaginalis; Processus Vag remains open, allowing fluid to come in via Peritoneal Cavity.
- Hematocele
  - Blood accumulation in testes
  - In response to injury, Hematoma

Varicocele
- When veins or Pampiniform plexus becomes dilated
- Result from Trauma or compromised blood flow
- More common on L. Side since it drains more indirectly, (via L. Renal v.)

Vasectomy
- Cut Vas Deferens
- Tie off
- All other aspects of Semen are fine, & Spermatogenesis is unaffected

Testes Lymph Drainage

Lymph is drained from testes & Epididymus into Lumbar IVC & Aorta nodes

Scrotal Lymph drainage goes to the Superficial Inguinal nodes

Inguinal Hernias

- Treatment: Sometimes can physically push it back in
  - If not, need Surgery

- Indirect Inguinal Hernia
  - More common in men
  - Pushes thru deep Inguinal Ring
  - In males, will be within the Spermatic Cord (w/ Ing. Ring)
- Direct Inguinal Hernia
  - Above Inguinal l., & within Median Inguinal Fossa
  - Directly thru Inguinal Ring
  - NOT in Spermatic Cord
  - Contents are just Parietal Peritoneum & Transversalis Fascia (thinner than Indirect)
- Femoral Hernia
  - Inf to Inguinal Canal & into Femoral Δ, in thigh

Omentum

Serosal membrane that spans from Organ -> Organ

- Lesser Omentum
  - Spans from Stomach & duodenum to the Liver
  - Hepatogastric l. - from Stomach to liver
  - Hepatoduodenal l. - Duod to Liver
  - Surrounds Hepatic portal Triad (Hepatic Portal v., Proper Hepatic a. & Bile Duct)
- Greater Omentum
  - Adipose that drapes over Abdom
  - Thin abdom viscera & body wall
  - "Abdominal Policeman"; clumps to area of infection
  - 3 Parts:
    1) Gastrophrenic l. - Stomach to Diaphragm
    2) Gastrosplenic l. - From Stomach to Spleen
    3) Gastrocolic l. - Largest & loops around

Epiploic Foramen
- Located behind the Hepatoduodenal l.
- Posterior Structures: IVC & R. Crus of diaphragm (Retroperitoneal)
- Ant. Structures: Hepatic Portal v., Proper hepatic a. & Bile duct
- Inf: Duodenum
- Sup: Caudate lobe of Liver

Peritoneal Cavity / Peritoneal Cavity Mesentery Omentum

Mesentery

- Membranous extension from the post. Body wall to an Organ (Parietal to Visceral Peritoneum)
- Physical Support & Sta for Intestines
- Allows for Vasculature to go to organs

Falciform l.

Greater Sac

Greater Sac

- Supracolic l.: Stomach, Liver & Spleen
  - Above Colon
- Infracolic Compartment: SI
- Supra & Infracolic areas can communicate via Paracolic Gutters
  - Can be Problematic for infection
- Lesser Sac - Behind Lesser Omentum
  - Extends up behind liver & down to Greater Omentum (gastrocolic l.)

Liver
Lesser omentum
Pancreas
Falciform ligament
Stomach
Transverse colon
Duodenum
Mesentery
Transverse mesocolon
Transverse colon
Greater omentum
Jejunum
Parietal peritoneum
Ileum
Visceral peritoneum
Rectum
Rectovesical pouch
Urinary bladder

Int. Anterolateral Abdom Wall

Umbilical folds

Falciform Ligament
- Fold of Parietal Peritoneum
- Separates lobes of Liver
- Becomes Continuous w/ Visceral Peritoneum of Liver

Ligamentum Teres
- Adult Remnant of Umbilical v.

Median Umbilical Fold
- Remnant of Urachus (of Allantois)

Medial Umbilical Fold
- Remnant of Umbilical a's

Lateral Inguinal Fossa
- Post. to Deep Inguinal Ring
- Susceptible to INDIRECT Inguinal Hernia

Arcuate line

Lateral Umbilical Fold
- Covers the Inf Epigastric a

Median Inguinal Fossa
- Post. to Superf Inguinal Ring
- More susceptible to a DIRECT Inguinal Hernia

Supravesicle Fossa
- Space above Urinary Bladder; as it fills, it will fill up this space

Esophagus

- In Mediastinum, is covered by Adventitia
- In Abdom, covered by Serosa membrane
- 4 Constrictions:
  1) Upper esophageal Sphincter - by Cricopharyngeus
  2, 3) Middle - Tracheal Bifurcations
  4) Lower - Diaphragm?
- Concern here b/c foreign bodies or chemicals can damage
- Esophageal Hiatus is at Right Crus of Diaphragm (T10)
- L. & R. Crura attach Diaphragm to vertebral body
- Upper Esophagus drains to Azygos Systemic
- Lower Esophagus drains to Hepatic Portal v.

Esophageal Plexus
- Parasym via Vagus n.'s (Preganglionic Para)
- Synapse in Submucosa & Myenteric Plexuses
- Inc Peristalsis & Glandular Secretions
- Sympa via G Splanchnic n.'s (Presynp) T5-T9
- Synapse on Celiac ganglia, where Postganglionic follow R. Way of arteries (L. Gastric a) back to esophagus
- Dec Smooth muscle Contraction & dec gland sec

Esophageal Varices

- Anastomoses thru Portal Venous & Azygos (along walls of Esophagus)
- Liver problems cause Retrofection of blood to these areas, making the veins bulge, & can potentially rupture (v. Bad, blood in mouth)
- Cirrhosis

Pyrosis

- Heartburn / Acid Reflux
- Acid bypasses Pyloric Sphincter to get into esophagus; acid overwhelms mucosa

Foregut -> Esophagus, Stomach, Liver, Gall bladder, Bile ducts, Pancreas, Proximal Duodenum

Stomach

Esophagus Stomach

- 2-3 Liters capacity in adults; 30mL in Newborns

Cardiac Notch

Pyloric Antrum

Pyloric Canal

Pyloric Sphincter
- Strong, thick
- Closed as the Chyme is being digested

Cardia
- Cardiac Sphincter

Angular Incisure

Body

Fundus

Arterial Supply

Common Hepatic a

Left Gastric a.
- S - Lesser Curve of Stomach
- Celiac Trunk Branch

L. Gastroepiploic
- S - Greater Curve
- Celiac Trunk -> Splenic a.
- L. Gastroepiploic a.

Celiac Trunk
- Supplies to foregut

Proper Hepatic a.

R. Gastric a.
- Smaller than L. Gastric
- Branch of Proper Hepatic a
- (Gastric a.'s Suppl. LESSER CURVE)

R. Gastroepiploic a.
- S - Greater Curvature
- Epiploic = above Colon
- Celiac Trunk -> Common Hepatic a -> Gastroduodenal a.

Short Gastric a.'s
- S - Fundus

Gastroduodenal

Hepatic Portal v.
- Drainage of digestive organs into Liver

Lymphatics of Stomach

Gastric nodes
- 1° Nodes for Lesser Curve

Gastroepiploic nodes
- 1° for Greater Curve

Celiac nodes
- 2°, which then drain to Thoracic duct

Innervation of Stomach

Greater Splanchnic n.
- Preganglionic Sympa from T8-9 Trunks
- Synapse on Celiac Ganglia
- Postganglionic Synapse on Tunica Adventitia of arteries
- Inhib muscle contraction & Gland sec.

Vagal trunks
- Preganglionic Parasym
- Travel through Esophageal Hiatus
- Synapse in Stomach
- These postganglionic will inc Smooth muscle & Glandular Sec.

Stomach Cancer

- Tumors are Palpable
- Meds or Surgery
  - Gastrectomy -> Removal of part of Stomach for Ulcer, Cancer, weight loss. Has good healing

Stomach Ulcer

- Usually by H. Pylori
- Breaks down mucosa
- Treatment - Vagotomy (cut Vagus n. to help reduce parietal cell HCl).

Hiatal Hernia

- Upper part of Stomach bulges through diaphragm
- Age related
- Pain
- Sliding Hiatal Hernia -> Esophagus & Cardiac Sphincter are drawn up above Diaphragm; more common
  - Bending over or lying down will give Acid Reflux
- Para-esophageal Hiatal Hernia -> Part of Stomach herniates through, but not Esophagus. NO Acid Reflux

- Foregut - Celiac Trunk
- Midgut - Sup. Mesenteric
- Hindgut - Inf. Mesenteric

Duodenum

Transitions from Intraperitoneal to Retroperitoneal (mostly, Pelvis)

Duodenum
- Trust out to Pyloric sphincter & sits at level of L1

4 regions
- Superior
  - L1
- Descending
  - L1-3
  - Major Duodenal Papilla
  - Bile duct & Pancreatic duct open here (hepatopancreatic ampulla)
- Inferior
  - L3; hit to head of Pancreas
  - Crosses over Sup. Mesenteric a. & v.
- Ascending
  - L2

Duodenum

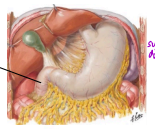

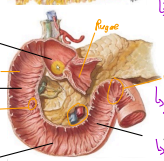

Artery Supply to Duodenum

- Sup. Pancreatico duodenal a.'s
  - Celiac Trunk → Common hepatic a. → Gastroduodenal a.
- Sup. Pancreatico duodenal a.'s
  - S-Major duodenal papilla (superior Duodenal Ones)
- Inf. Pancreatico duodenal a.'s
  - Branch of Sup. Mesenteric a.
  - Supplies inferior Duodenal ones (below Major papilla)

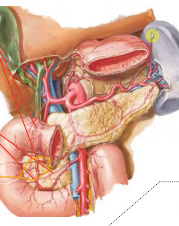

- Anastomoses
  - of vessels seen above
  - Marks transition of Foregut to Midgut
- Duodenojejunal flexure
  - Has a compressor, m. to help regulate flow

Duodenal Venous Drainage

- All drainage flows into Hepatic Portal v.

Lymphatic Drainage of Duodenum

- Pancreatico duodenal nodes
  - 1° nodes
- Celiac nodes
  - 2° nodes
  - Then to Thoracic duct

Duodenal Innervation

- Greater & Lesser Splanchnic n.'s
  - T6-9 & T8-10 Preganglionic Sympa
  - Synapse in Celiac & Sup. Mesenteric Ganglia
  - Reduce Glandular & muscle contraction
- Posterior Vagal Trunk
  - Preganglionic Parasymp
  - Plus stim Esophageal Motility
  - Synapse in Duodenum to induce Inc Glandular Sec & smooth muscle contraction

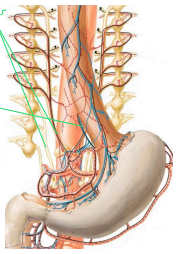

Hepatic Portal v.

- Brings majority of blood INTO Liver
- Blood is dirty, but rich in nutrients & Bilirubin (via spleen)

Splenic v.

Hepatic Portal

Sup. Mesenteric v.

Inf. Mesenteric v.

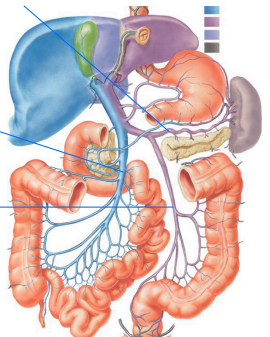

- The arterial & Bile Supply runs in the lines that separate the lobes
- S-End Arteries; No Anastomoses thus Segments
  - Beneficial for Surgery

Functional Lobes/Segments

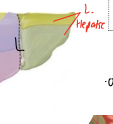

Proper Hepatic a.

- Oxy & nutrient blood

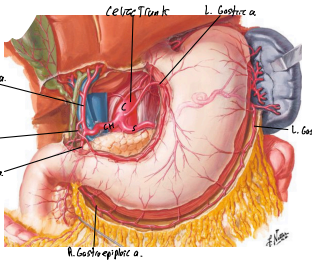

Liver

Functions:
- Carb metabolism & Storage
- Plasma protein & Lipoprotein Synthesis
- Bile Formation & Secretion
- Drug & Alc detox

- Bare area: no peritoneum or peritoneal Cavity between this area of liver & Diaphragm

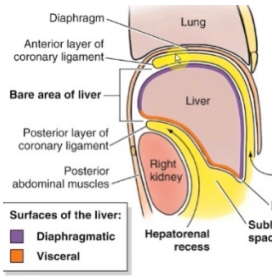

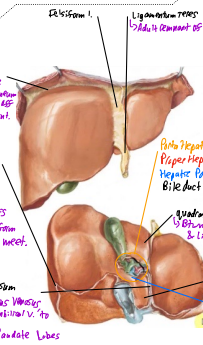

Cirrhosis of Liver

- Liver looks bumpy/nodule
- Associated w/ Chronic Alcoholism
- Hepatomegaly
- Portal Hypertension
  - Treatment is a Shunt to IVC

Cirrhosis

Gallbladder

Innervation of Liver

- Greater Splanchnic (T6-9)
  - Sympa, Synapse in Liver
  - Vasoconstriction
  - → Not TOO impactful
- Vagal Trunks
  - Para, Dilate Bile ducts & dec Bile flow
- Visceral afferents refer pain to mid-lower Thoracic on R. Side

Lymph Drainage of Liver

- Half of Lymph to Thoracic duct is made by Liver

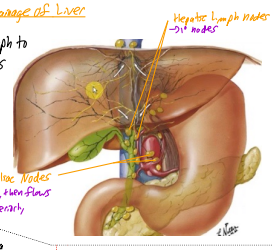

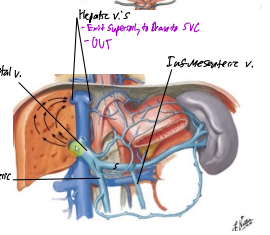

Biliary Duct System

- Function: Fat emulsification & Bilirubin breakdown
- Bile is being made 24/7 in liver, when we have too much build up, its stored in Gallbladder

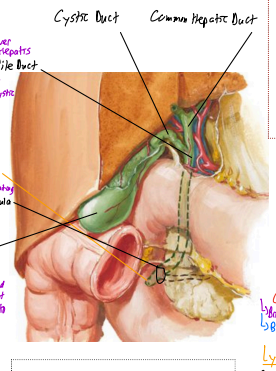

Biliary Duct System

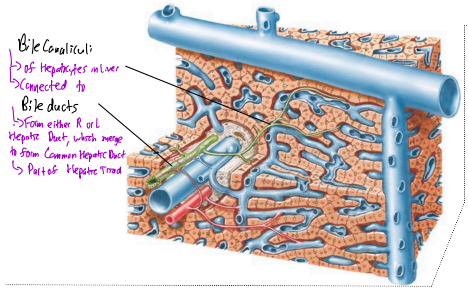

Cirrhosis Gallbladder

Gallbladder Supply & Drainage

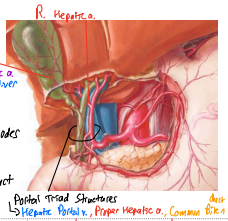

Lymph Drainage

- Cystic & Hepatic nodes are 1°
- Celiac node is 2°
- Then to Thoracic Duct

Gallbladder N

- Parasym
  - Vagal Trunks via Esophageal Plexus
  - Synapse in wall of Duct & Gallbladder
  - Relaxes smooth muscle to allow for better moving of Bile
  - Regulated by Cholecystokinin, which is triggered in response to a fatty meal, stimulates Parasymp
- Sympa
  - Greater Splanchnic n.
  - Reduce Bile activity by constricting Bile duct & smooth muscles of Gallbladder
  - Vagotomy causes dilation of GB
- Visceral afferents via T6-7 for pain on R. side

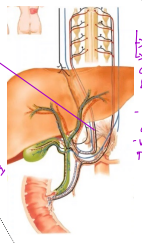

Gallstones

- Made of Cholesterol
- Small stones are worse cause they can get in the Duct system & cause blockages in distal regions
- As Bile gets backed up, it enters liver circulatory system, causing Jaundice
  - Can also back up in Pancreas
  - Pancreatitis
- Biliary Colic
  - muscle contractions to help push stones through bile duct, Pain
- Cholecystitis → Inflammation of GB
- Large stones often Asymptomatic
- Cholecystectomy → Removal of GB
  - NOT life changing

Spleen

- On L. around R9-11
- Intraperitoneal Organ
- Function: Cleaning out old RBCs using WBCs. This removes the iron, but creates Bilirubin, which is sent thru Splenic v. to liver
  - Also immunologically monitors body
- NOT a Vital Organ
- Intraperitoneal Organ

Medial Surface

- Concave

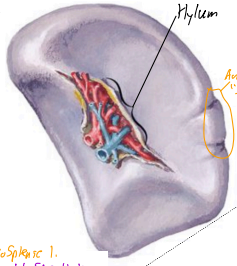

Spleen Lymphatic Drainage

- Pancreaticosplenic nodes - 1°
- Celiac or Sup. Mesenteric nodes - 2°
- Then efferent to Thoracic Duct

Innervation of Spleen

- Sympa
  - Greater Splanchnic (T6-8)
  - Synapse on Celiac Gang
  - Vaso Motor (Constrict)
- Parasymp
  - NONE

Spleen Rupture

- Ribs can lacerate it
- Lots of Bleeding
- Difficult to repair
- Treatment - Splenectomy
- If we lose our Spleen, our Bone Marrow & Liver will compensate for Erythropoesis

Pancreas

- Retroperitoneal
- Around L2
- Post to Stomach & Liver & between Kidneys
- Both Exo & Endocrine
  - Exo - Digestive
  - ENDO - Glucose regu in blood

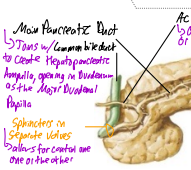

Spleen Lymph Drainage

- Pancreaticosplenic nodes 1°
- Celiac nodes 2°
- Efferent flow to TD

Spleen Innervation

- Sympathetics
  - Greater & Lesser Splanchnic n.'s (T6-T10) (minimal) (accidental)
  - Synapse in Celiac & Sup. Mesenteric gang
  - Vasoconstrict & dec Secretion
- Visceral afferents
  - T6-T10
  - Deep back
- Parasymp
  - Vagal Trunks
  - Synapse in Pancreas
  - Inc Pancreatic Secretion

Pancreatitis

- Bile backup via Hepatopancreatic Ampulla is blocked
- Pancreatectomy - HARD

Pancreatic Cancer

- Obstructive Jaundice via tumors
- Most tumors arise from duct system
- Pain in duct system

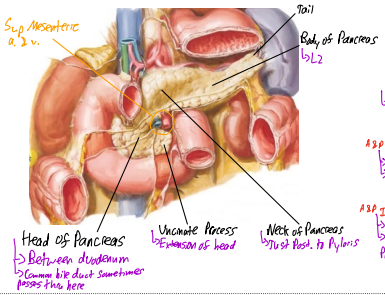

Pancreatic Vasc Supply & Drainage

- Drains to Hepatic Portal v.

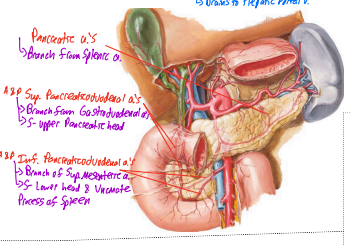

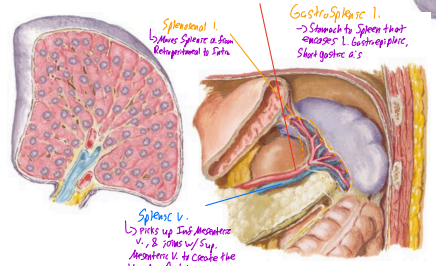

Jejunum Ileum

DISTAL to Major Duodenal Papilla Marks the MIDGUT

Jejunum

- Begins at Duodenojejunal Junction at point where Retroperitoneal Duodenum becomes Intraperitoneal
- Upper left of SI
- Intraperitoneal; Suspended by Mesentery
- Thicker Wall than Ileum

Ileum

- Ends at lower aspect of Ascending Colon
- Located in lower R. Abdomen
- Intraperitoneal

Functions of SI

- Nutrient Absorption

Vasculature of Jejunum & Ileum

- Sup. Mesenteric a.
  - S-ALL MIDGUT Structures
  - Branch of Abdom Aorta
  - Emerges from neck of Pancreas & flows down Mesentery
  - Jejunal & Ileal a.'s
- Arcades
  - Jejunal are Longer & Less Stacked
  - Ileal Arcades are Shorter & MORE Stacked
- Vasa Recta
  - From Arcades to Organs

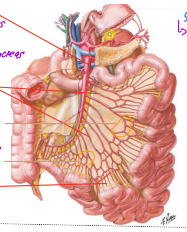

Veins of Jejunum & Ileum

- Sup. Mesenteric v.
  - Drains to Hepatic Portal v.
- Lymph
  - 1° - Mesenteric nodes
  - 2° - Sup. Mesenteric nodes
  - Efferent to TD

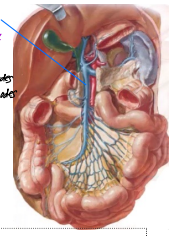

N-Jejunum & Ileum

- Greater Splanchnic
  - T8-T10
  - Sympa
  - Synapse on Celiac & Sup. Mesenteric Gang
  - Vasoconstrict, Reduce Motility of Smooth m. & Reduce Secretion
- Visceral Afferents
  - Pain referral along T8-10 Dermatomes
- Vagal Trunks
  - Parasym
  - Synapse in Submucosal & Myenteric Plexus
  - Vasodilate, inc Motility, Inc Sec.

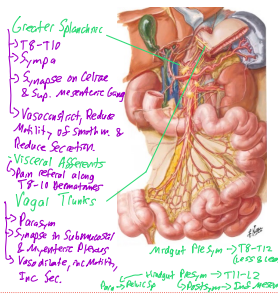

mesentery

- Double layered peritoneal structure that spans from Peritoneal Peritoneum of Post Wall to Visceral Peritoneum of Organs
- Attaches from Duodenojejunal junction to the Ileocecal Junction
- Functions:
  - Support
  - Inc SA
  - Gives Pathway for Vasculature & Lymph to Organs

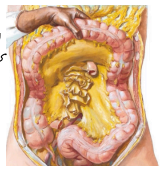

Large Intestine

- Functions to resorb electrolytes, water & other materials, then compact into Feces
  - Storage of Feces
- Begins at Cecum

LI

Teniae Coli
- 3 strips of outer Longitudinal muscle along Peritoneum (mesoteniae Externa)
  - Allow for bulging (Haustra)

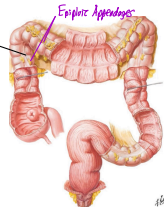

Cecum

- Cecum
  - Intra peritoneal

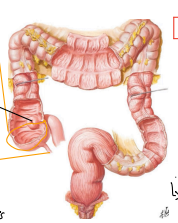

- Ileocecal Valve prevents backflow of foodchyme to SI

Appendix

- Extension of Cecum
- Lots of Lymph tissue
  - Appendix constantly monitors contents of LI
- Has its own Mesentery

Appendicitis

- Swollen nodes of Appendix is more common in young people
- Fecalith - Clogged area around appendix
  - More common in Older People
- Appendix rupture will expell all the infectious material into Peritoneal Cavity
- Appendectomy
  - Appendix isn't too important.

Ileal Diverticulum

- occurs in 1-2% of people
- Omphalomesenteric Duct remains & can fuse with body wall near umbilicus
- Can get inflamed & mimic Appendicitis

Supply & Drainage for Cecum & Appendix

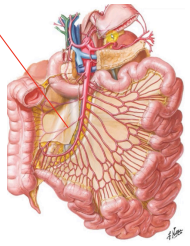

- Ileocolic a.
  - Branch of Sup. Mesenteric a.
  - S- Cecum, Appendix & lower Ascending Colon
- Ileocecal v.
  - Drains to Sup. mesenteric v. then to Hepatic Portal v.

Lymph Drainage

- 1° Ileocolic lymp nodes
- 2° Sup mesenteric nodes
- TD

N- Cecum, Appendix & A. Colon

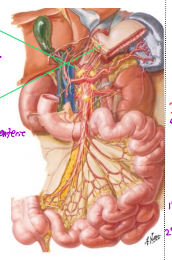

- Sympa (Lesser Splanchnic)
  - T10
  - Synapse of Sup. Mesenteric & Ileocolic ganglia
  - Visc Afff in T10
- Para Symp (Vagal Trunks)
  - Synapse in Submucosa & Myenteric Plexuses around a's & in Colon walls

Ascending Colon

- Retroperitoneal
- Paracolic Gutter
  - Open area between Body wall & Colon
- R. Colic a.
  - Branch of Sup. Mesenteric a
  - S- R. side of Colon
  - Feed into Marginal a.
  - Runs along whole Colon
- Ileocolic a. also S- A. Colon
- R. Colic v.
  - Drains to Sup. Mesenteric v.
- A. Colon Lymph
  - 1° - Paracolic, Ileocolic & R. Colic nodes
  - 2° - Sup. Mesenteric
- R. Colic Flexure
  - Bend
  - AKA Hepatic Flexure

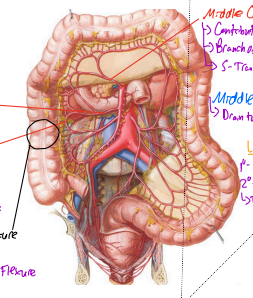

- Middle Colic a.
  - Contributes to Marginal a
  - Branch of Sup. Mesenteric a
  - S- Transverse Colon
- Middle Colic v.
  - Drain to Sup. Mesenteric v.
- Lymph
  - 1° - Middle Colic nodes
  - 2° - Sup. Mesenteric
  - TD

Transverse Colon

- Longest & most Mobile
- Intraperitoneal
- From R. Colic Flexure (Hepatic Flexure) to L. Colic Flexure (Splenic Flexure)
- Attachment site for Greater Omentum on its Sup.
- On its MS, there is the transverse mesocolon
- Transition to Hindgut at about 2/3 across

N- Sympa
- Lesser Splanchnic n. (T11) visc Afff
  - Follows Middle Colic a.
- Para Symp
  - Vagal Trunks
  - Synapse in Submucosa & Myenteric Plexus of Transverse Colon.

Blood Flow:

- Mid Gut - Sup. Mesenteric
- Hind Gut - Inf. Mesenteric

Descending Colon

- Hindgut
- Spans from Splenic Flexure to Iliac Fossa of Pelvis
- Retroperitoneal
- Like Ascending Colon, has Paracolic gutter in between Body wall & Colon, & is continuous from Infra & Supra Colic Sacs (of Greater Sac)

Inf. Mesenteric v.
- Drains to Splenic v. which drains to Hepatic Portal v.

Left Colic a.
- Branch of Inf. Mesenteric
- Connects to Marginal a, & this area of Marginal a is v. Important because it connects L & R Colic a.

Lymph Drainage
- 1° - Paracolic & L. Colic nodes
- 2° - Sup & Inf. Mesenteric nodes
- → TD

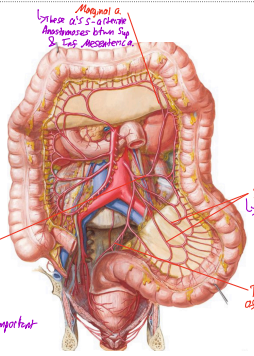

- Marginal a.
  - Where a's S- anterior Anastomoses between Sup & Inf. Mesenteric a.
- Sigmoidal a's
  - S- Sigmoid Colon
- Terminal Branch of Inf. Mesenteric a.

Sigmoid Colon

- Pelvic Coli Step of Rectum
- Short Mesentery, (Sigmoid Mesocolon)
  - Make Flexible
- Rectum around S3
- Intra Peritoneal
- Rectum becomes Retroperi

N- Descending & Sigmoid Colon

Sympathetics
- Lesser Splanchnic n. (T12)
- & Lumbar Splanchnic n.'s (L1-3)
- Synapse in Mostly Inf. Mesenteric
- Dec Peristalsis

Aside
- Thoracic & Lumbar Splanchnic fibers Carry Pain Sympa
- Pelvic Splanchnic fibers Carry Pain Para

Parasymp
- Pelvic Splanchnic n.'s (S2-4)
- Pass thru Inf. Hypogastric Plexus & Synapse in walls of Descending & Sigmoid Colon
- Inc Gland sec, Peristalsis

Visceral Afferents
- Distal to mid Sigmoid Colon will accompany Sympathetics (closer to urinary)
- Abroad to mid Sigmoid will accompany Parasymp

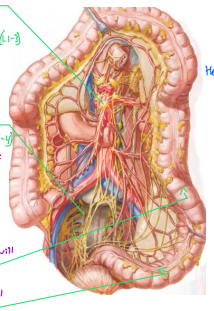

Hepatic Portal v. Anastomoses

Esophageal v. to Azygos v.
- Esophageal varices

Rectal v. → Inf. Mesenteric
- ↓ Sup. Mesenteric ← Splenic v.
- Hepatic Portal v. → Liver → IVC

Paraumbilical v.'s → Sup. Epigastric v.
- Caput Medusae
- Spider webs around umbilicus
- External indicator that venous drainage is compromised

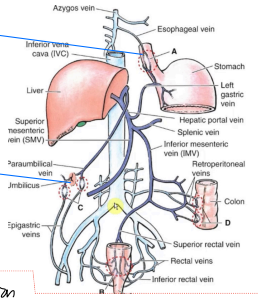

Portal Hypertension

- If Something is wrong w/ liver, this will hinder blood flow
- Dilation of one of the 3 above Esophageal Varices
  - Can bleed & become life threatening
- TREATMENT:
  - Portacaval Anastomosis; Hepatic (Portal v. & IVC.)
    - helps bypass some of blood to go directly into IVC & NOT liver (negates some liver function)
  - Liver Transplant.

Kidney

- Located under Thoracic Diaphragm
- R. Kidney lower due to Liver
- Adjacent to Psoas Major
- Nerves of Post Abdom (Subcostal, Iliohypogastric & Ilioinguinal) pass Posterior to kidney's
- Function: Filter blood, manage H_2O & Salts, Regulate BP & Erythropoiesis

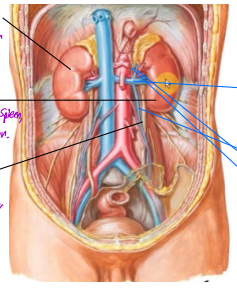

- R. Kidney
  - near Liver, Duodenum & Stomach
- L. Kidney
  - near Stomach, Spleen, Pancreas & D. Colon.
- Ureter
  - Urine flow from kidney's → Bladder

Kidney | Ureter

Veins of Kidney
- Each kidney has 1 Renal v.
- L. Renal v. is longer cause it has to pass over midline to get to IVC
- 3 veins drain to the L. Renal v.
  - L. Gonadal v.
  - Supra Renal v.
  - Inf. Phrenic v.

Lymph of Kidney
- 1° - Lumbar nodes
  - Then to TD

Arterial S- Kidney

- Similar to Liver, the Supply is Segmental via End arteries
- Ant. Ramus forms 3 Segmental a's
- Posterior Ramus forms 2 Segmental a's
- (5 end arteries)

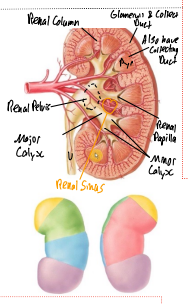

- Perirenal Fat → Surrounds Kidney & Adipose of Kidney
  - Contains Suprarenal Glands (Adrenal glands)
    - → NE & E, Androgens, Corticosteroids
- Para Renal Fat → Just Superficial to Perirenal Fat for Protection & allows for Kidney's to move via Respiration.

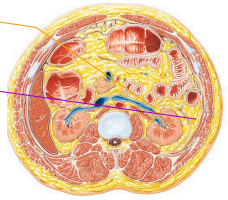

Ureter

- Retroperineal
- 3 Constrictions:
  1) Junction between Renal Pelvis & Ureter
  2) Across Pelvic Brim
  3) Through Urinary Bladder

Arter. Supply
- Renal a., Gonadal a., Aldom aorta a.

Venus Drainage
- Renal v., Gonadal v.

Lymph Drain
- 1° Lumbar or Iliac nodes → TD

Renal & Ureteric Calculi

- Kidney Stones; Ca^{2+} deposits
  - Can obstruct urine; backup of kidney, Hydronephrosis
    - Squeeze & kill of Nephrons
  - Lithotripsy,
    - Break up Kidney stones via Sound waves
- Sharp, rhythmic pain felt during every Peristaltic Contraction
- If Stones in Kidney, Ipsilateral pain
- If in Ureter, pain felt there
- Pain resolved when in Bladder

N- Kidneys

- Sympa - Lesser & Least Splanchnic (T10-12)
  - Synapse in Aorticorenal Ganglia
  - Vasoconstrict (Reduce urine output)
  - Visceral Afff - Post T10-12
- Para Symp - Post. Vagal Trunk
  - Synapse in Kidney
  - Vasodilation - Inc Urine

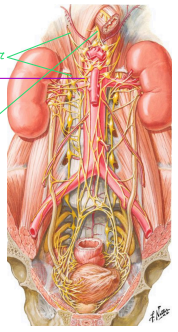

N- Ureter

- Sympa - Lesser & Least & Lumbar Splanchnic (T11-L2)
  - Inc Peristalsis
- NO Para

Suprarenal Glands

- Right Glands just to R. of IVC
- Left Glands just L. of Left Crus of Diaphragm
- Cortex
  - Functions to produce Corticosteroids & Androgens
  - NO N in Cortex (Hormonal)

Adrenal | Suprarenal

- Medulla
  - Secretes E & NE
  - N- Pre Sym (Lesser & Least Splanchnic)
  - Some Sympathetic Pass through the ganglia w/o Synapsing & go Straight to Suprarenal Medullar cells secretes

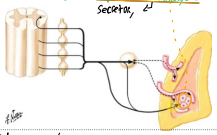

Arterial Supply to Adrenals

- Middle Suprarenal a.
  - Branch from Aorta
- Sup. Suprarenal a's
  - Branch from Inf. Phrenic
- Inf. Suprarenal a's
  - Branch from Renal a.
  - Tons of Small a's

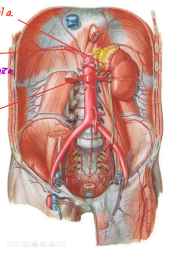

Venous Drainage of Suprarenals

- R. Suprarenal v.
  - Drains directly to SVC
- L. Suprarenal v.
  - Drains to L. Renal v.
- Lymphatics
  - 1° nodes - Lumbar nodes
  - Efferent TD

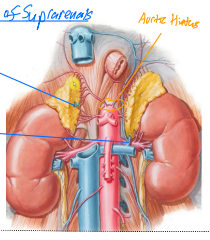

Renal / Ureteric Anomalies

- Bifid Pelvis / Ureter

Horseshoe Kidney

- During development, kidney's are supposed to be pulled up into body. This can be limited via Inf. Mesenteric a.
- Asymptomatic

Ectopic Pelvic Kidney

- Stays in pelvis during dev.
- Asymptomatic unless in Pregnant Woman.
- Arteries will branch from Iliac a.

Thoracic Diaphragm

- Pericardiacophrenic ligaments cause Heart & Pericardium to move Inferiorly, with Diaphragm upon Inspire
- Diaphragm moves Sup when Suspire
  - Can cause Dyspnea cause organs make it more difficult to Flatten Diaphragm.
- N- Phrenic n.
  - Runs between Pericardium & Mediastinal Parietal Pertoneum
  - Referred Pain Centralized to neck (C3-5)
  - Peripheral pain goes to Rib segment
- Attaches to Ribs 6&7 Centrally, & 10-12 peripherally
- Attaches posteriorly to Rib 12

Diaphragm

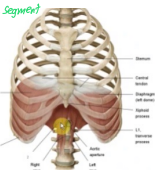

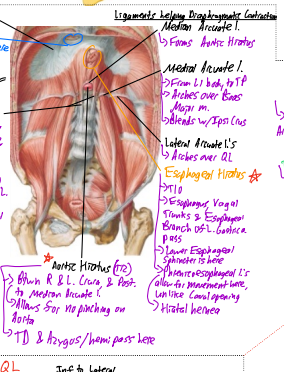

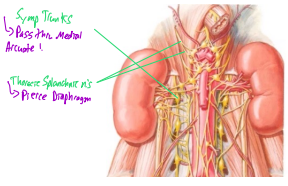

Diaphragm Arterial Supply

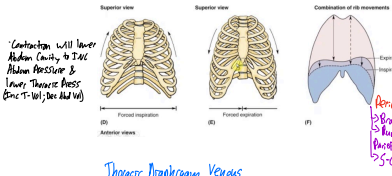

- Contraction will lower Abdom Cavity to IVC Abdom Pressure & Lower Thoracic Press (Inc T-Vol; Dec Abd Vol)

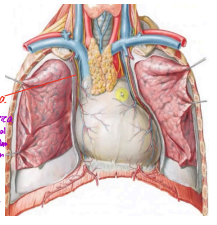

- Pericardiacophrenic a.
  - Branch of Int. Thoracic
  - Run between Mediastinal Parietal Pleura & Pericardium
  - S- Central Diaphragm
- Sup. Phrenic a.
  - Branch of Desc Thoracic Aorta
  - S- Post. Thoracic Diaphragm

Thoracic Diaphragm Venous

- Central & Peripheral Superior regions drain to Internal Thoracic v.
- Posteriorly, will drain to Azygos
- Inf. drainage is Asymmetrical

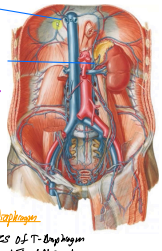

- R. Inf. Phrenic v.
  - Drains straight to IVC
- L. Inf. Phrenic v.
  - Drains to L. Renal v.

Lymphatics of Diaphragm
- Abdominal Lymphatics of T-Diaphragm are 1° S- for Peritoneal Fluid Absorption
- 1° nodes are Ant & Post Diaphragmatic nodes
- 2° are Parasternal & Post. Mediastinal Nodes
- → TD

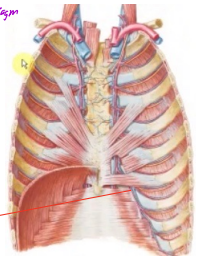

- Inf. Phrenic a.
  - Branch of Abdom Aorta
  - S- Inf. Surface of Diaphragm (fine most Supply)
- Musculophrenic a.
  - Branch of Int Thoracic
  - S- Peripheral parts of Thoracic Diaphragm

Hemidiaphragm Paralysis

- Injury to phrenic n. on one side
  - Causes one side to not work
  - Half of Diaphragm causes reduced air's flow, but can still function
  - On Radiograph, HUMMED Hemidiaphragm will be more Superior
  - Paradoxical Movement; one side will contract, creating more Abdom pressure & push other side up

Hiccups

- Spasm of diaphragm
  - Air is getting sucked fast, causing Glottis walls to snap shut (sound)
  - Irritation

Psoas Major

- Goes under Arcuate l.
  - O: T12-L5 Bodies, discs & TP's
  - I: Lesser Trochanter
- N- L1-L3
- A- Hip flex; torso or thigh
  - Psoas minor
    - Present in some
- Passes deep to Inguinal l.

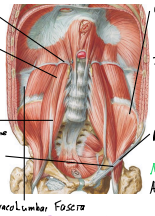

Iliacus m.

- O- Iliac crest, lateral Sacral Ala (Post. & Lateral to Psoas major).
- I- Merger w/ Psoas major under Inguinal l. to create Iliopsoas, which inserts on Lesser Trochanter

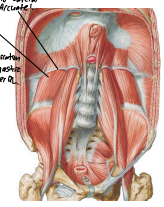

QL

- O- Rib 12 & L1
- I- Iliac Crest
- N- T12-L4 VRR
- A- Lat. Flex Torso & Stabilization of Respiration
  - Subcostal & Iliohypogastric & Ilioinguinal pass over QL

Inf. to Lateral Arcuate l.

Endo Abdominal Fascia

- Similar to Transversalis Fascia
- Nerves of Lumbar Plexus located here

Thoracolumbar Fascia
- Extension of Int. Oblique & Transversus abdom
- Wraps around QL

Psoas Major | Iliacus

Thoracolumbar Fascia

- Thin in Thoracic area
- Thicker in Abdom
- Medial Attachment ↳ SPs from Lower Ribs to Iliac Crest
- QL is between Ant. & Mid layer of Ant's fascia

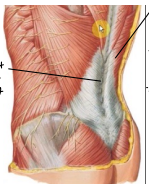

- Lateral Attachment is at Transverse Abdom & Int. Oblique
- Erector Spinae is in mid layer
- Multilayered Fascia Creates Strong Integrity for Post Abdominal Wall

Psoas Sign

- Psoas is near many organs, so if the organs are unwell, movement of the muscle can cause irritation
- Pt. lies on unaffected side & extends affected side against RS
  - ↳ if painful; same disorder

Fascial Abscesses

- Psoas abscess
- Can only spread within the fascial sheath
  - ↳ Can spread superior up to higher vertebrae

Abdominal ANS

- Sympa Ganglia - Prevertebral
- Parasymp Ganglia - within Target Organs

Autonomic Plexuses

- ↳ Contain both Sympa & Parasym
- ↳ Prevertebral
- ↳

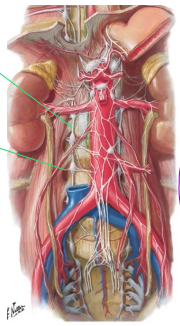

Lumbar Sympa Trunk

↳ Continuous w/ Thoracic & Sacral Trunks

Pregang Sympathetics

- ↳ From T1 - L2
- ↳ Pass into chain via WRC

Splanchnic n.'s

- ↳ Pregang Sympa, T5-L2
- ↳ Synapse in Prevertebral Tissue/Ganglia
- ↳ Lumbar are Sympa & mainly do Vasoconstriction to inhib GI activity
- ↳ Run medially

Visceral Afferents

- ↳ Dermatomes of the are damaged via Sympa Trunk

Parasymp

- ↳ Vagal Trunks & Pelvic Splanchnic n.'s
- ↳ Vagal enters Abdomen via Esophageal Plexus through Esophageal Hiatus
  - Pregang gets to organs via vasculature
- ↳ Pregang Parasymp
  - S2-4
  - Hindgut & Pelvic Viscera
  - Synapse in walls of Organs

Lumbar Plexus

Lumbar Plexus of N's

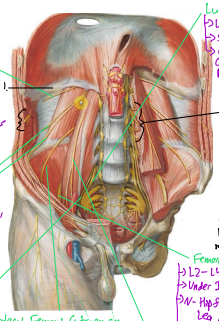

Subcostal nerve

- ↳ Ventral Rami - T12
- ↳ Passes under Lateral Arcuate l.
- ↳ Then runs between Transversus Abdom & Int. Oblique
- ↳ N- All 3 lateral Oblique n.'s
  - Sensory to Anterolateral T12 dermatome

L1 - 2 branches:

- Sup
  - Ilioinguinal n. - Scrotum/Labia
- Inf
  - Iliohypogastric n. - Sup. Inguinal
- ↳ Run between Transversus Abdom & Internal Oblique
- Terminate as Sensory N's over Scrotum & Anterior Pubic area

Obturator n.

- ↳ L2-L4
- ↳ Runs thru Obturator Canal to get to Medial thigh
- ↳ N- Muscles of Med thigh
- ↳ N- Adductors

Lateral Femoral Cutaneous n.

- ↳ Contributions from L2 & L3
- ↳ Crosses over Iliacus
- ↳ N- Lateral thigh sensory

Femoral Branch

- ↳ Stays over Femoral △

Genital Femoral n.

- ↳ L1-2
- ↳ On Anterior Surface of Psoas Major
- ↳ Genital Branch
- ↳ N- Cremaster m. & Anterior Scrotal Sac/Labia Majora.

Femoral n.

- ↳ L2-L4
- ↳ Under Inguinal l., into Femoral △
- ↳ N- Hip flexors & Quads/anterior Leg muscles
- ↳ N- Anteromedial Leg sensory, via Saphenous

Lumbosacral Trunk (not N)

- ↳ L4 & L5
- ↳ S1-3 on Ala
- ↳ Carries L4/L5 fibers to connect Lumbar & Sacral Plexuses
  - Ventral Rami
  - ↳ Lumbar Plexus within Psoas major m.
  - ↳ L1-L3 all contribute to Lumbar Plexus
- Post. Sympa neurons enter the Lumbar Sympa Trunk via White Rami, then ascend/descend the Lumbar Trunk, out Grey Rami, to Gut Ventral Rami to N. Smooth muscle, exocrine & glands

No White Rami Communicantes below L2, since Pregang Sympa spans from T1-L2

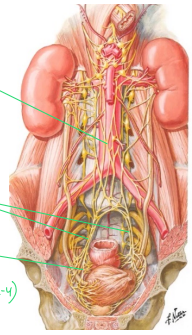

Celiac Plexus

- ↳ Postgang Sympa fibers & Pregang Para (from Vagal Trunk)
- ↳ Mainly Greater & Less Splanchnic n.'s
- ↳ SDI Sympa
- ↳ N- Foregut

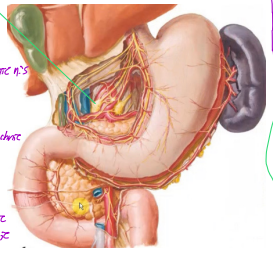

Superior Mesenteric Plexus

- ↳ Sympa via Lesser & Least Splanchnic
- ↳ Parasym via Post. Vagal Trunk
- ↳ Mostly, Midgut Structures

Inf Mesenteric Plexus

- ↳ Sympa via Lumbar Splanchnic
- ↳ Parasym via Pelvic Splanchnic
- ↳ Mainly, Hindgut

Sup. Hypogastric Plexus

- ↳ Surrounds Distal Aorta
- ↳ Sympa via Lumbar Splanchnic
- ↳ Parasymp via Pelvic Splanchnic
- ↳ Ureter & Gonads

Hypogastric n.'s

- ↳ Provides Communication btwn Sup & Inf Hypogastric Plexuses

Inf Hypogastric Plexus

- ↳ Sympa via Lumbar Splanchnic n.'s
- ↳ Parasymp via Pelvic Splanchnic (S2-4)
- ↳ Pelvic Viscera

Abdominal Blood vessels & Lymph

- 3 unpaired Visceral Branches
  - ↳ Celiac Trunk, Sup & Inf Mesenteric a.'s
- Paired lateral Visceral Branches
  - ↳ Renal a.'s, Middle Suprarenal a., & Testicular/Ovarian a.'s
- Paired Parietal Branches
  - ↳ Subcostal, Inf. Phrenic, Lumbar a.'s (all supply body wall)

Abdom Aortic Aneurysm

- Loss of elasticity causing reduced collagen, which creates a large bulge
- Pulse can be palpable
- Can leak & blood accumulates; bleed out
- Treatment
  - ↳ Can reinforce a graft

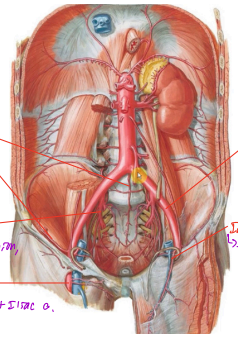

IVC Abdom Aorta

- Median Sacral a.
- Deep Circumflex a.
  - ↳ Branch of Ext. Iliac a.
  - ↳ S- Ant. Pelvis
- Internal Iliac a.
  - ↳ S- Pelvis, gluteal Region, & Perineum
- Femoral a.
  - ↳ Continuation of Ext Iliac a.
- Ext Iliac.
- Inf Epigastric a.
  - ↳ S- Rectus sheath

IVC Tributaries

- IVC does not have valves
- Drains everything Inf to thoracic diaphragm EXCEPT GI structures (Hepatic Portal v.)
  - ↳ but Hepatic Portal v. blood does eventually get to IVC

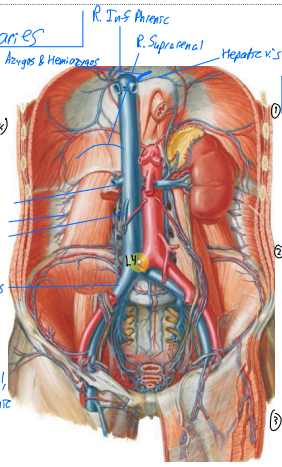

- R. Inf Phrenic
- R. Suprarenal
- Azygos & Hemiazygos
- Hepatic v.'s
- Renal v.'s
- Lumbar v.'s
- R. Gonadal v.
- Common Iliac v.'s

Collaterals to get around IVC:

1. ↳ Ext Iliac v.
   - ↳ Inf Epigastric v.
   - ↳ Sup Epigastric
   - ↳ Int Thoracic
   - ↳ Brachiocephalic
   - ↳ SVC

   &

2. ↳ Femoral v
   - ↳ Great Saph
   - ↳ Superficial Epigastric
   - ↳ Lateral Thoracic
   - ↳ Axillary
   - ↳ Subclavian v.
   - ↳ Brachiocephalic
   - ↳ SVC

   • Thoracoepigastric v. will become engorged

3. Lumbar v. ⟶ Epidural Plexus
   - SVC ⟵ Azygos System

- To Left Renal v., but not R.; L. Gonadal, L. Suprarenal & L. Inf Phrenic

Posterior Abdom Wall Lymphatics

- Lower limb & Abdomen drainage goes into the Cisterna Chyli
  - ↳ Convergence of Lymph tissue just left to diaphragm } becomes TD
- Nodes All along Aorta
- Inguinal Nodes:
  - 1° for
  - ↳ Lower limb, Perineum, Butt & Lower Ant. Body Wall
  - ↳ Then to External & Common Iliac Nodes
- Internal Iliac Nodes:
  - 1° for
  - ↳ Pelvic Urinary, Pelvic rectum & Pelvic genital organs
  - ↳ 2° to Common Iliac & Lumbar nodes
- Lumbar Nodes
  - 1° for
  - ↳ Suprarenal, Kidney, Ovary/Testes, & Post. Body Wall
  - ↳ 2° to Common Iliac, Celiac, Inf & Sup Mesenteric Nodes